A REVIEW OF PULMONARY HOMOGRAFT STENOSIS AFTER THE ROSS PROCEDURE

Talat Chughtai* Thao Huynh Jean Francois Morin

ABSTRACT

The Ross Procedure involves pulmonary autograft replacement of the aortic valve with homograft reconstruction of the RVOT. Although this procedure has many advantages compared to standard aortic valve replacement, one of the complications we have experienced is pulmonary homograft stenosis (PHS). We report on six cases out of a total of 32 patients having undergone the Ross Procedure (19%) who developed varying degrees of PHS. Two patients are symptomatic (6%), with one patient (3%) requiring reoperation at four years after implant. This phenomenon has been reported by a few others and theories as to its etiology include an immune mediated reaction to the homograft. Our six patients all experienced fever of unknown origin post-operatively and histologic analysis of the explanted homograft showed changes suggestive of a possible immune cause for the stenosis, in the form of a chronic low grade rejection. PHS seems to occur early (within one year post-implant) and then appears to plateau. It is a complication that may be seen more as follow-up time increases and its etiology, whether immune or not, will be elucidated as experience with reoperation for PHS grows. PJCTS 2000; II: 38-44.

INTRODUCTION

Pulmonary autograft replacement of the aortic valve (Ross Procedure) was first described and applied in 1967[1]. Its use as a permanent valve replacement in young patients with aortic valve disease has steadily increased over time and there is now universal acceptance of the use of a cryopreserved homograft for right ventricular outflow tract (RVOT) reconstruction[2]. There have been, however, reported cases of pulmonary homograft stenosis in the recent literature as well as experimental work to try and determine its cause. We report six cases of pulmonary homograft stenosis that we have observed in our experience after the Ross Procedure. One patient required reoperation, and pathologic analysis of the explanted homograft revealed a possible immune cause for the stenosis. A brief review of the literature on this subject is also included.

MATERIAL AND METHOD

We have performed the Ross Procedure in 32 patients with aortic stenosis. The same technique was used in all patients. Briefly, it involves valve and root replacement of the diseased aortic valve with the native pulmonary valve and artery (with reimplantation of the coronary arteries) and RVOT reconstruction with a cryopreserved pulmonary homograft. The homograft is swen proximally (at the level of the infundibulum) and distally (below the pulmonary artery bifurcation) with a single running suture of 4/0 prolene. All patients receive pre-operative intravenous (IV) 1st generation cephalosporin and myocardial protection is achieved using continuous retrograde cold blood cardioplegia.

Pre-operatively, the pulmonary annulus diameter is determined using trans thoracic echocardiography (TTE) in all patients. Intra-operatively, before anaesthetic induction, all patients are assessed with trans esophageal echocardiography (TEE). This is repeated post-operatively, after coming off cardiopulmonary bypass, for functional assessment of both aortic and pulmonary conduits. Trans esophageal echocardiography (TEE) is performed in all patients prior to discharge and yearly, beginning at six months post-operative. Peak instantaneous and mean gradients across the pulmonary homograft are

*Address for correspondence:
Department of Cardiac Surgery and Cardiology
Montreal General Hospital
McGill University Health Center
Montreal, Canada

measured in order to detect, among other things, obstruction to flow.
Six of the 32 patients (19%) have developed varying degrees of pulmonary homograft stenosis post-operatively, as determined by higher than normal gradient across the pulmonary valve on TTE. The peri-operative characteristics of these patients are shown in Table I.
The first patient was the only one whose homograft was undersized at the time of the original operation and he developed a tear at the pulmonary infundibulum requiring reanastomosis of the conduit. Since then, we prefer to use a valve at least 1 mm greater in size than the measured annulus diameter, and have had no technical difficulties.
Table II demonstrates the occurrence of fever of unknown origin (FUO), as well as elevated white blood cell (WBC) count, post-operatively in six patients who developed pulmonary homograft stenosis. Fever which is generally low grade, resolved spontaneously without any treatment.
Figure 1 graphically shows the TTE evolution of the fate of the pulmonary homograft post-operatively in six patients who developed homograft stenosis. Three of the patients developed high mean gradients across the pulmonary valve relatively early post-operative (within one year), after which the gradient seems to plateau.
Table-III shows that only two patients out of 32 (6%) are symptomatic, and that the stenosis is occurring at the supravalvular, valvular, as well as subvalvular level. Only one patient (3%) was severely symptomatic due to obstructive process in the pulmonary valve; the gradient was the highest, with a peak instantaneous gradient of 92 mmHg (mean of 58 mmHg). This patient recently needed reoperation for pulmonary homograft stenosis (reoperation rate of 3 %); at four years post-operatively, we performed a replacement of the pulmonary homograft with another cryopreserved homograft. This time, a homograft one size larger than the previous one was used (21 mm vs. 19 mm). The previous homograft was opened and almost completely resected, leaving the posterior wall in-situ, and the new conduit was sown in place. Of note, the RVOT was grossly shrunken in size and when the old homograft was opened, there was a moderate stenosis at the valvular and supravalvular level of the conduit. Both previous anastomosis were visualized and appeared normal.
The resected specimen was sent for histological analysis. It showed extensive dense collagenous adventitial fibrosis associated with small lymphocytic aggregates. These histologic changes suggested a possible immune cause for the observed stenosis, in the form of a chronic low grade rejection, rather than being related to a technical problem.

DISCUSSION

The experimental work of Shumway and Lower with autologous tissue valves and the lack of an optimal aortic valve prosthesis, led Ross to pursue the concept of a pulmonary autograft procedure[3]. Increased availability of cryopreserved homografts and documented safety of the procedure, with excellent and reproducible results[4], has steadily led to its increased use. The advantages of the Ross Procedure are: easy conformability (and therefore optimal function) of the pulmonary valve in the aortic position, long-term viability and growth potential in young patients, and avoidance of long-term embolic and anticoagulation risks associated with mechanical valves[1,4,5]. These are counterbalanced, however, by increased technical difficulty of the procedure and the risk of early and late valve failure requiring re-operation of either the autograft or the homograft RVOT reconstruction[2]. In this discussion, we concentrate on the occurrence of pulmonary homograft stenosis after the Ross Procedure.
The procedure involves removing the patient's own pulmonary valve along with the main trunk of the pulmonary artery and using it to replace the aortic valve. It can be placed either in the orthotopic subcoronary position or as a root replacement with reimplantation of the coronary arteries[1], as we have done in all of our cases. Autograft root replacement appears to have a reduced incidence of early failure[2]. The RVOT is usually reconstructed with a cryopreserved pulmonary homograft inserted in the normal anatomic position[1,2]. When choosing a suitable pulmonary homograft, it is usually better to err on the larger size[1]. Except in our 1st case, we have also erred

on the larger size. As mentioned previously, we perform our proximal anastomosis on the pulmonary homograft side using a running prolene suture. It is worth noting that at the 30th Annual Course in Cardiac Surgery in May of 1999 in London, England, Professor Magdi Yacoub performed this anastomosis in an interrupted fashion. Also of note is the comment by Dr. Ross himself that he performed the anastomosis in a running fashion.

Few studies have reported pulmonary homograft stenosis in their experience with the Ross Procedure. Kouchoukos et al[5] reported one 15 year old patient out of 33 (3%) developing circumferential supravalvular stenosis at 16 months (peak gradient of 65 mm), treated with a pericardial patch repair. Seven patients, however, retained moderate gradients (mean of 26 mm) above the pulmonary valve but did not need reoperation. Ross[6] himself reported on 241 patients in whom a pulmonary homograft was used in 26, with one patient needing replacement (3.8%).

Elkins[2] reported five patients (out of 195) patients undergoing the Ross Procedure; 3%) needing reoperation of the pulmonary homograft secondary to supravalvular stenosis at 1 to 5.4 years after the operation. Four were treated directly with a 2nd homograft replacement (one of these was restenosed and treated with balloon angioplasty and an intravascular stent). The 5th was initially treated with a patch angioplasty, but two years later required homograft replacement for recurrent stenosis. Ward et al[7] evaluated their intermediate fate (mean follow-up three years) of cryopreserved homografts in 1154 patients having undergone the Ross Procedure. They found that mean homograft annulus size decreased significantly by 15% and that the obstruction developed most often at the supravalvular level (usually within one year of implant). Two of their patients (1.6%) required reoperation for pulmonary homograt stenosis. The International Registry of the Ross Procedure[3], set up to measure clinical outcome of this operation since 1993, has found 18 cases of reoperation for pulmonary homograft failure out of 2523 patients (1.3%). They report a freedom from RVOT revision of 96%, 90% and 84% at 5, 10 and 20 years respectively. Most of the events take place in the first three years. At the recent meeting of the Society of Thoracic Surgeons (STS) (not yet published), the group from Toronto reported on their experience with the Ross procedure. They found elevated peak systolic gradients across the pulmonary homograft in 35% of the 105 patients having undergone the procedure; one needing reoperation twice for pulmonary homograft stenosis. Our six patients (out of 32) have high gradient across the pulmonary valve, but only one (3%) has needed reoperation for it at four years after implant.

Although the thinner pulmonary artery wall (vs. aortic) should make it less prone to calcification, and the low pressure right side should better tolerate a stenosis if it does occur[6,8], there have been a few report of reoperation for pulmonary homograft stenosis. Cleveland et al[9] reported on 132 patients who received cryopreserved pulmonary homografts for reconstruction of the RVOT for congenital heart disease, with 27 (15%) requiring reoperation for calcific stenosis was seen distally, proximally, and as a diffuse process. There analysis revealed no relationship between stenosis and either body surface area, homograft size, method of processing, or ABO compatibility. They thus suspected the stenosis to be secondary to conduit rejection, but suggested that more detail immunological analysis was needed. Recently, several studies have addressed this specific issue (see below). The stenosis in our cases also varied to involve the supravalvular, valvular, or subvalvular component of the pulmonary homograft. It has also been recently shown that the Ross Procedure leads to significantly increased pulmonary peak flow velocities even in oversized cryopreserved homografts[10]. In the Toronto group's presentation at the recent STS meeting, they oversized the pulmonary homograft by 2.5 mm. Their analysis showed that independent predictors of late pulmonary homograft stenosis (mean follow-up of 40 months) included younger donor age (<30) and shorter duration of cryopreservation (<20 months). Based on this, they concluded that pulmonary homograft stenosis may be related to increased cell viability causing an inflammatory reaction.

Three clinical studies have looked at the immune response to aortic allografts post-operatively. Fischlein et al[11] found that in the first three weeks post-operative, all homograft valves caused an immunologic reaction (greater in ABO incompatible grafts) that lasted a mean of three days which resolved spontaneously. Yacoub's group[12] showed that homografts stimulate a strong donor HLA specific antibody response (IgG) that can persist for 15 years after the procedure, but questioned its clinical significance. Hogan et al[13] found that donorspecific IgG to class I and II HLA is first detected at 30 days in the serum of all aortic allograft recipients, that persisted at one year. They also found increased T-cell alloreactivity toward donor WBCs, particularly high at 30 days. They concluded that cryopreserved aortic valve allografts elicit a substantial allogenic response in recipients and may contribute to morphologic changes which may eventually lead to long term deterioration of allograft function.

An elegant animal study performed by Neves et al[14] studied the mechanism underlying degeneration of cryopreserved vascular homografts, comparing cryopreserved homograft and autograft, as well as fresh autograft. They showed that cryopreserved homografts undergo profound changes affecting all strata and that WBC infiltrates are found up to one year after implantation not seen in other specimen groups; thus suggesting an immunologic reaction, rather than the cryopreservation process itself, is responsible for the observed degeneration process.

As mentioned, all six patients in our report who eventually developed pulmonary homograft stenosis, experienced FUO post-op with a concurrent elevation in WBC count, which resolved spontaneously. In our patient with the highest gradients requiring reoperation, although technical factors related to undersizing of the conduit would likely have contributed to the eventual stenosis, the pathologic analysis of the explanted homograft did show signs suggestive of a possible chronic low grade reaction. This was based on the fact that this type of reaction, involving intimal thickening and fibrosis, is similar to what we have observed in chronic low grade rejection after cardiac transplantation Shapira et al[15] also reported on FUO after aortic valve replacement with cryopreserved allografts. They defined FUO as a temperature greater than 38.3 degrees Celcius occurring on or after the 3rd post-operative day with a negative work-up. It occurred in 26% of patients, most commonly from fourth to sixth post-operative days, and lasted for 24-48 hours with resolution without any treatment. There was not consistent associated elevated WBC count and they found no relation of the fever to bypass or cross-clamp time, ABO matching, or perioperative blood transfusions. They concluded that a significant number of patients who undergo aortic valve replacement with a cryopreserved allograft develop a non infectious fever post-operatively that may reflect a low grade rejection.

As reported by a few, and as we ourselves were recently involved with one case requiring reoperation, pulmonary homograft stenosis does occur after the Ross Procedure. Based on Ross's observation of accelerated degeneration and early failure occurring in patients receiving cryopreserved allografts and not in patients reconstructed with a cadaveric, antibiotic sterilized homograft, Elkins[2] suggests that if homograft failure does occur, it is an uncomplicated, safe and satisfactory procedure to replace it with another pulmonary homograft. If a second failure then occurs, it should be replaced with a cadaveric, non viable valve or a cryopreserved homograft treated with immunosuppressives. We used another cryopreserved homograft to replace the old conduit in our patient undergoing reoperation. Carpentier's group[16] recently reported on their early experience (up to 20 months follow-up) in 20 patients with a new approach to reconstruct the RVOT during the Ross Procedure. This consists of a direct anastomosis between the remaining pulmonary artery (PA) trunk and the infundibulum, with the creation of a monocusp tailored from the anterior PA wall. There was no significant pressure gradient across the pulmonary monocusp in any patient. They thus suggest this technique as an alternative for RVOT reconstruction if these results continue to persist at long-term follow-up.

The Ross Procedure is the procedure of

choice for young patients with aortic stenosis. It has had an established advantage in patients less than 30 years of age, with a controversial role in older patients. However, because of accelerated failure in young patients (<30) associated with Bioprosthetic valves, and the inherent thromboembolic and anticonagulation risks with mechanical valves, it is increasingly being used in older patients. A recent review[4] of 30 years of use of the Ross Procedure supports its use in young patients, women of child bearing age, and in patients with congenital aortic stenosis and complex LVOT obstruction.

The procedure, however, is associated with any of a number of complications, including what we and a few others have described as pulmonary homograft stenosis. This stenosis seems to occur in 1-6% of cases and appears to involve accelerated degeneration in the form of early calcific stenosis. This stenosis can occur at any level with respect of the valve and may represent the end result of an immunologic reaction in the form of a chronic low grade rejection whose only sign may be low grade fever early post-operatively. We suggest that patients should be followed up at least yearly to detect this potential complication. Our findings of six patients with pulmonary homograft stenosis occurred in the subgroup of patients operated on earlier in our series, and thus with longer follow-up. Perhaps with equally long follow-up in the remainder of patients, a greater number of such cases will be observed.

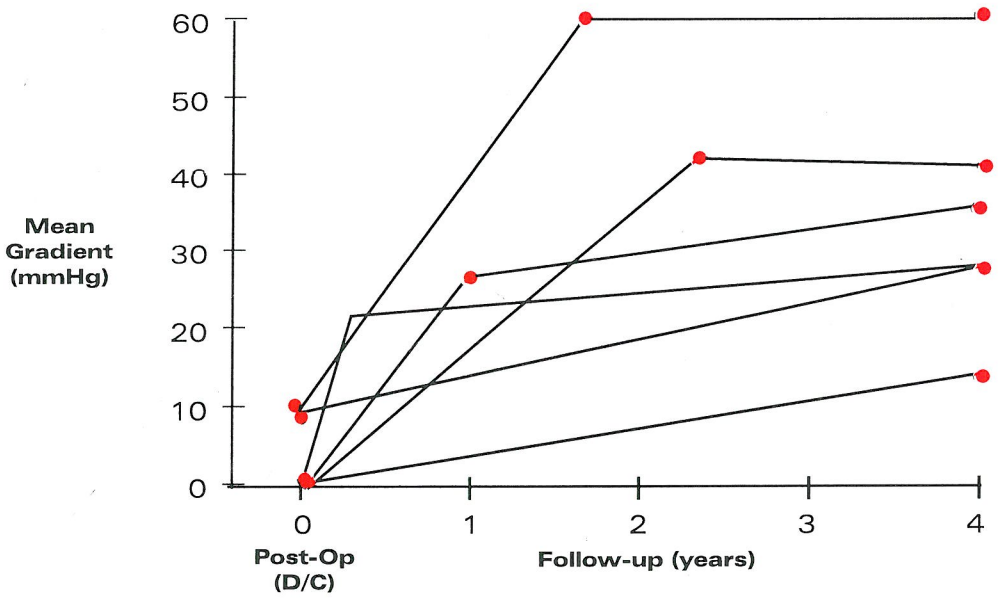

Figure-I

TABLE-I

Peri-op details of patients developing homograft stenosis after Ross Procedure

Patient	Age/Sex	Pulm. annulus size (mm)	Pulm. Homograft size (mm)	Bypass/x-clamp time (min)	Transfusion (# units)
1	48 M	21	19	156/109	21
2	38 M	25	26	155/116	0
3	55 M	21	22	107/90	3
4	43 M	22	23	133/112	2
5	27 M	25	25	195/145	0
6	41 F	25	24	259/158	24

TABLE-II

Post-op course of patients who developed homograft stenosis

Patient	Fever duration	T' max	WBC max
1	POD 3 to POD 4	38.2 (OPOD 3)	16.5 (OPOD 3)
2	POD 2 to POD 6	38.5 (OPOD 2)	20 (OPOD 2)
3	POD 4 to POD 7	38 (OPOD 6)	14.5 (OPOD 4)
4	POD 2 to POD 9	38 (OPOD 8)	17.9 (OPOD 8)
5	POD 2 to POD 12	38.5 (OPOD 2)	15.4 (OPOD 2)
6	POD 4 to POD 8	38 (OPOD 6)	12.4 (OPOD 2)

TABLE-III

Findings at last follow-up of patients with homograft stenosis

Patient	Symptom	Follow-up time	Gradient (peak, mean)	Level of stenosis
1	class III-IV SOB	4 years	92,58	valvular
2	asymptomatic	4 years	50,30	supravalvular
3	asymptomatic	4 years	65,41	valvular
4	mild SOBOE	4 years	54,36	supravalvular
5	asymptomatic	4 years	50,30	supravalvular
6	asymptomatic	4 years	27,18	valvular

REFERENCES

1. Ross D. Replacement of the Aortic Valve With a Pulmonary Autograft: The "Switch Operation". Ann Thorac Surg 1991:52:1346-50.
2. Elkins DC, Lane MM, McCue C. Pulmonary Autograft Reoperation: Incidence and Management. Ann Thorac Surg 1996;62:450-5.
3. Oury JH. Hiro SP. Maxwell M. Lamberti JJ. Duran CMG. The Ross Procedure: Current Registry Results. Ann Thorac Surg 1998;66:S162-5.
4. Oswalt JD. Acceptance and versatility of the Ross procedure. Current Opinion in Cardiology 1999;14(2):90-4.
5. Kouchoukos NT, Davila-Roman VG, Spray TL, Murphy SF, Perrillo JB. Replacement of the Aortic Root with a pulmonary Autograft in Children and Young Adults with Aortic-Valve Diseas. N Engl J Med 1994;330:1-6.
6. Matsuki O, Okita Y, Almeida RS et al. Two decades' experience with aortic valve replacement with pulmonary autograft. J Thorac Cardiovasc Surg 1988;95:705-11.
7. Ward KE, Elkins RC, Overholt ED et al. Evaluation of cryopreseved homografts in the right ventrucular out flow tract after the Ross procedure: intermediate-term follow-up. J Heart Valve Disease 1997;6(2):130-3.
8. Livi U, Abdulla A-K, Parker R, Olsen EJ, Ross DN. Viability and morphology of aortic and pulmonary homografts. J Thorac Cardiovasc Surg 1987;93:755-60.
9. Cleveland DC, Williams WG, Razzouk AJ et al. Failure of Cryopreserved Homograft Valved Conduits in the Pulmonary Circulation 1992;86(suppl II):II-150-II-153.
10. Moidle R, Simon P, Kupilik N et al. Increased pulmonary flow velocities in oversized homografts in patients after the Ross procedure. Eur J Card-Thorac Surg 1997;12(4):569-73.
11. Fischlein T, Schutz A, Haushofer M et al. Immunologic Reaction and Viability of Cryopreserved Homografts. Ann Thorac Surg 1995;60:S122-6.
12. Smith JD, Ogino H, Hunt D, Laylor R, Rose M, Yacoub MH. Humoral immune Response to Human Aortic Valve Homografts. Ann Thorac Surg 1995;60:S127-30.
13. Hogan P, Duplock L, Green M et al. Human Aortic Valve Allografts Elicit a Donor-Specific Immune Response. J Thorac Cardiovasc Surg 1996;112:1260-7.
14. Neves JP, Gulbenkian S, Ramos T et al. Mechanisms Underlying Degeneration of Cryopreserved Vascular Homografts. J Thorac Cardiovasc Surg 1997;113:1014-21.
15. Shapira OM, Fonger JD, Reardon K, Shemin RJ. Unexplained Fever After Aortic Valve Replacement With Cryopreserved Allografts. Ann Thorac Surg 1995;60:S151-5.
16. Couetil JP, Berrebi A, Ferdinand FD et al. New approach for reconstruction of the pulmonary outflow tract during the Ross procedure. Circulation 1998;98(suppl 19):II368-71.